



Asian Journal of Research in Pharmaceutical Sciences and Biotechnology

Journal home page: www.ajrpsb.com



EVALUATION OF SEXUAL BEHAVIOUR ON *PUNICA GRANATUM* (Linn.) RIPE FRUIT EXTRACT IN MALE RATS

D.Suvarna^{*1}, M.Jalaiah², D.Dhachinamoorthi³

¹*QIS College of Pharmacy, Vengamukkapalem, Ongole, Andhra Pradesh, India.

²Department of Pharmacology, QIS College of Pharmacy, Vengamukkapalem, Ongole, Andhra Pradesh, India.

³Department of Pharmaceutics, QIS College of Pharmacy, Vengamukkapalem, Ongole, Andhra Pradesh, India.

ABSTRACT

Reproduction is initiated by mating of male with a female in sexual intercourse which facilitates the coming together of sperm and egg for the purpose of fertilization. Sexual dysfunction effectively is a major problem facing the reproductive process. In ayurvedic medicine *Punica granatum* (Linn) is a fruit-used as aphrodisiac. *Punica granatum* (Linn) extract showed significant equal effect in sperm count and % of sperm motility when compared to Sildenafil and Testosterone administered rats, significant increase in sperm count and % of sperm motility when compared to Stressed rats. In case of histopathology of testis, treatment of *Punica granatum* (Linn.) extract in the rats overcomes the single layer of spermatogenesis, congested blood vessels and absence of spermatozoa due to stress and produces Thickening of basement membrane, predominance of spermatocytes, increase in no.of sertoli cells and maturation arrest in few seminiferous tubule cells.

KEYWORDS

Punica granatum (Linn), Aphrodisiac, Spermatogenesis and Sexual dysfunction.

Author for Correspondence:

Suvarna D,
QIS College of Pharmacy,
Vengamukkapalem, Ongole,
Andhra Pradesh, India.

Email: darsinamsuvarna@gmail.com

INTRODUCTION

For life to continue, an organism must reproduce itself before it dies. In Homo sapiens, reproduction is initiated by mating of male with a female in sexual intercourse which facilitates the coming together of sperm and egg for the purpose of fertilization. For there to be a normal sexual intercourse and sexual fulfilment in males, the male sexual organs (the copulatory organ, the penis) and factors relating to erection must function normally. Male sexual dysfunction (MSD) could be caused by various factors. These include: psychological disorders, androgen deficiencies, chronic medical

conditions (diabetes, hypertension), vascular insufficiency (atherosclerosis, venous leakage), penile disease (peyronie's, priapism, phinosis, smooth muscle dysfunction), pelvic surgery (to correct arterial or inflow disorder), neurological disorders (parkinson's disease, stroke, cerebral trauma, alzheimer's disease, spinal cord or nerve injury)¹.

Synthetic drugs like sildenafil citrate, vardenafil citrate, tadalafil citrate, yohimbine and phentolamine are used for erectile dysfunction, but these drugs also have fatal side effects like vasodilatory in nature (e.g., headache, flushing, nasal congestion), with gastrointestinal(dyspepsia) and abnormal vision².

Hence, there is an increasing demand for the alternative therapies, particularly herbal therapies that are believed to be effective, safe and economical. *Punica granatum* (Linn.) Family: puniceae is a fruit-bearing deciduous shrub or small tree cultivated in many parts of India. The unripe fruit is a good appetizer and tonic, useful in vomiting, lessens inflammation, and in keratitis. The ripe fruit is tonic, laxative, diuretic, enrich the blood, used in sore throat, scabies, bronchitis, astringent to the bowels and aphrodisiac³.

However, there is no authentic scientific data reported regarding aphrodisiac activity of *Punica granatum* (Linn.) ripe fruits. In this context, in the present study an attempt is proposed to evaluate the effect of *Punica granatum* (Linn.) ripe fruit extract on aphrodisiac activity and stress modulated sexual behavior in male rats.

REVIEW OF LITERATURE

Plant description

Punica granatum(Linn.) is distributed from the Balkans to the Himalayas and cultivated in many parts of India³.

Punica granatum(Linn.) is a large deciduous shrub or small tree, bark smooth, grey, thin; often armed with terminal thorns. Leaves opposite, 2.5-6.3cm.long, oblong-lanceolate, oblong-elliptic or oblong-oblongeolate. Flowers 3.8-5cm. long and as much cross, mostly solitary, sometimes 2-4 together, terminating short shoots, sometimes apparently axillary, sessile or nearly so. Fruit 3.8-

7.5 cm. diameter, globose tipped with calyx-limb, rind coriaceous, woody, the interior septate with the membranous walls of the carpels each carpel containing numerous seeds angular from mutual pressure. Seeds with a watery outer coat containing pink juice and horny inner coat³.

Synonyms³

- English : Pomegranate
- Hindi : Anar
- Sanskrit : Dadimba
- Telugu : Danimma
- Kannada : Dalimma
- Tamil : Madulam
- Malayalam : Dadiman

Parts used

Bark, flowers, leaves, ripe fruit, peel and seeds³.

Chemical constituents

Pomegranate aril juice provides about 16% of an adult's daily vitamin C requirement per 100 ml serving, and is a good source of vitamin B₅ (pantothenic acid), potassium and antioxidant polyphenols³.

Other phytochemicals include polyphenols catechins, gallo catechins, and anthocyanins such as prodelphinidins, delphinidin, cyanidin, and pelargonidin³.

Medicinal uses⁴

The root is an external vermicide. The bark is astringent, strengthens the gums, used in piles, prolapsusani and colic. The bark and seeds are useful in bronchitis. The flowers are useful in epistaxis, styptic to the gums, check vomiting, useful in biliousness, sore eyes, ulcers, sore throat, and applied to hydrocele. The unripe fruit is a good appetiser and tonic, useful in vomiting; causes biliousness.

The ripe fruit is tonic, astringent to the bowels, aphrodisiac, laxative, diuretic, enrich the blood, allays thirst, used in sore throat, sore eyes, brain diseases, spleen complaints, chest troubles, scabies and earache. The rind of fruit is anthelmintic;

METHODOLOGY

Effect on Stress modulated sexual behavior in male rats⁵⁻⁸

Male Albino rats weighing between (150-200 g) were divided into following seven groups of six rats each, in which three groups were for hydro alcoholic extract of *Punica granatum*(Linn.) in a dose of 100,200 and 400mg/kg respectively as low medium and high doses.

Group 1

Normal control (receives distilled water 3ml/kg) (without stress) p.o.

Group 2

Stress control (receives distilled water 3ml/kg) p.o.

Group 3

Standard drug (sildenafil citrate 0.7mg/kg)p.o.

Group 4

Standard drug (testosterone 15mg/kg) p.o.

Group 5

High dose of hydro alcoholic extract of *Punica granatum*(Linn.) p.o.

Group 6

Medium dose of hydro alcoholic extract of *Punica granatum*(Linn.) p.o.

Group 7

Low dose of hydro alcoholic extract of *Punica granatum*(Linn.) p.o.

All the treatments were given for 28 consecutive days before Immobilization stress.

Induction of Immobilization stress

The animals were subjected to IMB stress by Plexiglas cylinder (5 cm diameter and 16 cm large) for 6 h a day during light period started from 10 am each day for 28 consecutive days. Water and food were withdrawn during stress period.

Sperm count

1. Spermatozoa were collected by flushing the vas deferens and epididymis in 2.0ml of normal saline,
2. Draw the semen in the WBC pipette up to 0.5 mark,
3. Draw in 4% sodium bicarbonate in 1% phenol solution up to the mark 11, making a dilution of 1 in 20
4. count the sperm under high power in the four WBC squares

Calculation

Number of sperms in 1 cu.mm of sample = $N \times 10/4 \times 20$
Number of sperms in 1 ml (i.e.1 cu.cm) of sample: = $N \times 50 \times 1000$ (as 1 cu.cm=1000cu.mm)= $N \times 50,000$

Where N is the total sperm count observed in outer four square of WBC chamber

Sperm motility

Place a drop of semen on the cover slip and invert it on a rim of plasticine on the cavity slide. Examine under high power objective and find out the percentage of immobile to mobile sperms.

Histology of testis

Two-left testis of each group was excised and rinsed in 0.9% saline blotted dry of saline and excess blood. They will be fixed in 12 % formalin for 24 hr. The tissues, after fixation, were washed in water to remove excess fixative. Washed tissues were dehydrated through a graded series of ethyl alcohol, cleared with xylene and embedded in paraffin wax. Sections were cut at 3 μ m with microtone blade, and mounted on clean glass slide. The sections were routinely stained with haematoxyllin and eosin. The stained slides were observed (400 X) in research microscope and photographed.

Histopathology results of rat testis

Normal histology of testis was seen, seminiferous tubules were closely packed, normal arrangement of the basement membrane below this presence numerous spermatogenic cells and spermatozoa also found, the lumen was occupied by the tail sperms. Thickening of basement membrane, single layer of spermatogenic cells found and congested blood vessels were present with no spermatozoa were absent. Normal maintenance of basement membrane, prominent spermatogenesis and presence of spermatozoa at the center of each cell. Maintenance of basement membrane, less number of sperm cells, delayed maturation and prominent primary spermatocytes. Thickening of base ment membrane, predominance of spermatocytes, increase in no.of sertoli cells and maturation arrest in few seminiferous tubule cells. Thickening of basement membrane, predominance of spermatocytes and increased number of sertoli cells. Thickening of basement membrane, maturation arrest and Increased number of sertoli cells.

DISCUSSION

The sperm count and sperm motility obtained from high dose of hydro alcoholic extract of *Punica granatum*(Linn.) were similar to sildenafil citrate and testosterone. The twenty eight days treatment with sildenafil citrate, testosterone, high, medium and low doses of *Punica granatum*(Linn.) extract showed significant increase in sperm count and % of sperm motility when compared to stressed rats. In stress control group of rats, there was slight decrease in sperm count and slight increase in % of sperm motility when compared to normal control group of rats. (Table No.1 and Table No.2)

In histopathological study of testis of normal control group of rats, normal histology of testis was seen, seminiferous tubules were closely packed, normal arrangement of the basement membrane below this presence of numerous spermatogenic cells and spermatozoa also found, the lumen was occupied by the tail sperms.

In stress control group of rats, there was thickening of basement membrane, single layer of spermatogenic cells found and congested blood vessels were present with no spermatozoa.

In sildenafil citrate treated group of rats, normal maintenance of basement membrane, prominent spermatogenesis and presence of spermatozoa at the center of each cell. This revealed that sildenafil citrate can show prominent results in stress

conditions also as it retained the histology as that of normal control animals.

In testosterone treated group of rats, there was maintenance of basement membrane, less number of sperm cells, delayed maturation and prominent primary spermatocytes. This supports the earlier results, and is a potent drug for treatment for stress induced sexual dysfunction.

In *Punica granatum*(Linn.) extract high dose treated group of rats, there was thickening of basement membrane, predominance of spermatocytes, increased in no.of sertoli cells and maturation arrest in few seminiferous tubule cells indicating that the drug is less potent in comparison to standard drugs like sildenafil citrate and testosterone, but useful for stress induced sexual dysfunction.

In *Punica granatum*(Linn.) extract medium dose treated group of rats there was thickening of basement membrane, predominance of spermatocytes and increased number of sertoli cells, this indicates that the extract at this dose was able protect the cell from damage as in case of stressed rats.

In *Punica granatum*(Linn.) extract low dose treated group of rats, there was thickening of basement membrane, maturation arrest and increased number of sertoli cells. There was no development of spermatocytes revealing that the extract at this dose may not be protecting the testis from damage.

Table No.1: Effect of sildenafil, testosterone and *Punica granatum* extract on Sperm Count (Total x 10⁵) in stress modulated rats

S.No	Treatment	Sperm Count (Total x 10 ⁵)						Mean±SEM
		1	2	3	4	5	6	
1	Normal Control	100.0	125.0	118.0	122.5	120.0	112.5	118.0±2.363
2	Stress Control	197.5	112.5	104.0	92.5	105.0	109.0	103.4±3.004
3	Sildenafil	207.6	214.5	232.5	263.0	258.5	232.0	234.6±9.169**
4	Testosterone	274.0	256.5	269.5	267.0	247.5	259.5	262.3±3.964**
5	P.G.H (400 mg/kg)	268.5	268.0	243.5	273.5	259.5	220.0	255.5±8.306**
6	P.G.M	155.0	162.5	161.5	167.5	190.5	173.5	168.4±5.090**
7	P.G.L	132.5	142.5	145.0	136.0	140.5	144.0	144.0±1.998**

Values are Mean ± SEM (n=6) one way ANOVA followed by Dunnett's 't' test.

Where ** represents very significant at p< 0.01 when compared to stress control group.

P.G.H(400 mg/kg), P.G.M(200 mg/kg) and P.G.L(100 mg/kg) are the high, medium and low doses of *Punica granatum*(Linn.)

Table No.2: Effect of sildenafil, testosterone and *Punica granatum* extract on sperm motility (%) in stress modulated rats

S.No	Treatment	Sperm Motility (%)						Mean±SEM
		1	2	3	4	5	6	
1	Normal Control	45	50	52	40	47	46	46.6±1.706
2	Stress Control	46	43	49	51	50	45	47.3±1.282
3	Sildenafil (0.7mg/kg)	82	77	80	79	74	88	80.0±1.949**
4	Testosterone (15 mg/kg)	75	85	78	82	76	70	77.6±2.171**
5	P.G.H (400 mg/kg)	75	83	72	68	74	76	74.6±2.028**
6	P.G.M (200 mg/kg)	65	67	63	72	68	61	66.0±1.592**
7	P.G.L (100 mg/kg)	60	59	56	63	67	55	60.0±1.826**

Values are Mean ± SEM (n=6) one way ANOVA followed by Dunnett's 't' test.

Where ** represents very significant at $p < 0.01$ when compared to stress control group.

P.G.H(400 mg/kg), P.G.M(200 mg/kg) and P.G.L(100 mg/kg) are the high, medium and low doses of *Punica granatum*(Linn.)



Figure No.1: *Punica granatum* Trees



Figure No.2: *Punica granatum* Flowers




Figure No.3: Histopathology of testis of normal control rats




Figure No.4: Histopathology of testis of stress control rats

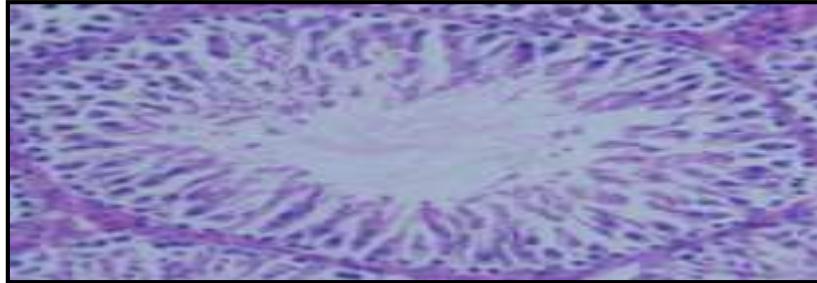


Figure No.5: Histopathology of testis of sildenafil citrate (0.7mg/kg) treated stressed rats

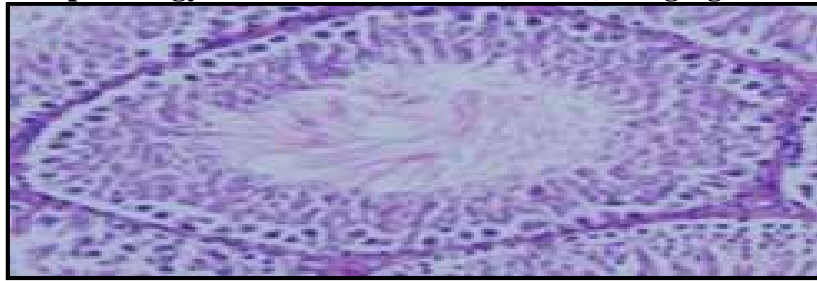


Figure No.6: Histopathology of testis of testosterone (15 mg/kg) treated stressed rats

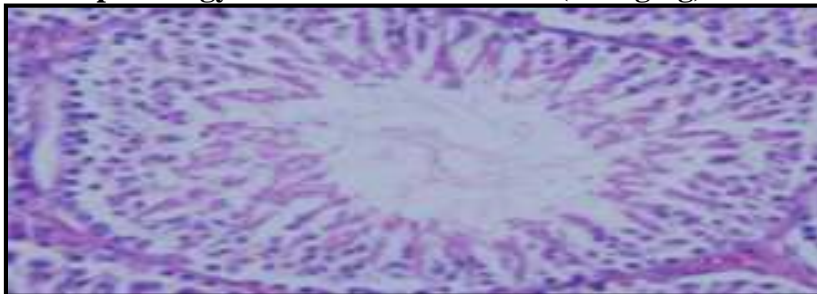

Figure No.7: Histopathology of testis of high dose of *Punica granatum* extract (400 mg/kg) treated stressed rats




Figure No.8: Histopathology of testis of medium dose of *Punica granatum* extract (200 mg/kg) treated stressed rats

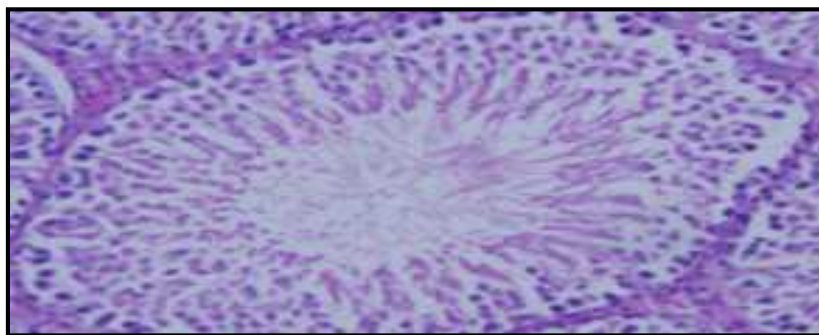


Figure No.9: Histopathology of testis of low dose of *Punica granatum* extract (100 mg/kg) treated stressed rats

CONCLUSION

From the results obtained, we conclude that the *Punica granatum*(Linn.) ripe fruit extract at higher doses produces significant and sustained increase in the sexual activity of normal male rats and also helpful in overcoming IMB stress induced sexual dysfunction. This activity may be due to the presence of different phytoconstituents viz, glycosides and flavanoids in the extract. However, further studies are required to isolate and identify the active constituent responsible for the activity and also to focus on the mechanism of its aphrodisiac activity.

ACKNOWLEDGEMENT

Authors are thankful to management of QIS college of Pharmacy, Ongole.

CONFLICT OF INTEREST

We declare that we have no conflict of interest.

BIBLIOGRAPHY

1. Yakubu M T, Akanji M A and Oladiji AT. Male sexual dysfunction and methods used in assessing medicinal plants with aphrodisiac potentials, *Phcog Rev*, 1(1), 2007, 49-56.
2. Soni M, Patidar K, Sharma D, Soni P, Sharma D K. Oral therapy for erectile dysfunction, *Asian J pharmaceuticals*, 3(3), 2009, 174-177.
3. Kirtikar K R and Basu B D. Indian Medicinal Plants. Periodical Experts Book Agency, *Dehra Dun*, 2nd Edition, 2(2), 1935, 1084-87.
4. <http://en.wikipedia.org/wiki/Pomegranate> access on 20th Jan'16.
5. University of Plymouth Department of psychology, Salmon study materials on-line, PSY128 Lecture Support Material, Hormones and Sexual Behavior. www.indopedia.org/environment access on 20th Jan'16.
6. Inoko M, Kiharay Y, Morii I, Fujiwara H, dasayana S. Transition from compensatory hypertrophy to dilated failing heart ventricles in Dahi-salt sensitive rats, *Am J Physiol*, 267(36), 1994, 471-482.
7. Jain A K. Manual practical physiology for MBBS, Semen analysis sperm count and motility, *Arya publications, Sirmour*, 1, 2003, 176-77.
8. Bauer J D, Ackerman P G, Toro G. Clinical Laboratory Methods. St. Louis Missouri, USA: *Mosby Co*, 8th Edition, 1974.

Please cite this article in press as: Suvarna D et al. Evaluation of sexual behaviour on *punica granatum* (Linn.) ripe fruit extract in male rats, *Asian Journal of Research in Pharmaceutical Sciences and Biotechnology*, 5(1), 2017, 6-12.